

S  
l  
i  
d  
e  
  
1

**Ourine**

*Covering Disease*  
*Morbo Coitale Maligno*  
*Slapsiekte, el Ourin*  
*Mal de Coit, Beschalseuche*  
*Sluchnaya Bolyezn*

S  
l  
i  
d  
e  
  
2

**Overview**

- Organism
- History
- Epidemiology
- Transmission
- Disease in Humans
- Disease in Animals
- Prevention and Control



In today's presentation we will cover information regarding ourine and the organism that causes disease. We will also talk about the history of ourine, how the organism is transmitted, and clinical manifestations of disease. Finally, we will address prevention and control measures and actions to take if ourine is suspected. [Photo: Horses in field. Source: USDA]

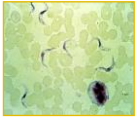
S  
l  
i  
d  
e  
  
3

**THE ORGANISM**

S  
l  
i  
d  
e  
  
4

**The Organism**

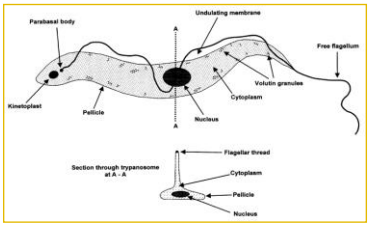
- Protozoan parasite
  - *Trypanosoma equiperdum*
- Closely related to other *Trypanosoma* spp.
  - *T. brucei* subsp. *brucei*
  - *T. brucei* subsp. *gambiense*
  - *T. brucei* subsp. *rhodesiense*
  - *T. evansi*
- Strains vary in pathogenicity



Ourine is caused by the protozoan parasite *Trypanosoma equiperdum*. This organism belongs to the subgenus *Trypanozoon* and *Salivarian* section of the genus *Trypanosoma*. It is very closely related to *Trypanosoma brucei* subsp. *brucei*, *T. brucei* subsp. *gambiense* and *T. brucei* subsp. *rhodesiense*, which cause African trypanosomiasis in a variety of species, and to *T. evansi*, which causes surra. Strains of *T. equiperdum* vary in their pathogenicity. [Photo: *Trypanosoma equiperdum*. Source: Image: <http://cal.vet.upenn.edu/projects/parasit06/website/lab2.htm>]

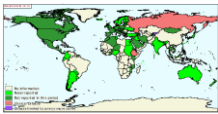
S  
l  
i  
d  
e  
  
5


**Trypanosome**



The diagram illustrates the fundamental features of a trypanosome (trypomastigote). The main diagram shows a side view of the parasite with labels for: Parasit body, Undulating membrane, Free flagellum, Volutin granules, Cytoplasm, Nucleus, Pellicle, and Kinetoplast. A smaller diagram below shows a 'Section through trypanosome w.A. 18', with labels for: Flagellar thread, Cytoplasm, Pellicle, and Nucleus.

[Photo: This is an illustration of the fundamental features of a trypanosome (trypomastigote) as seen in a stained preparation made from the blood of an infected animal. The parasite consists of a single cell varying in size from 8 to over 50 µm. Source: <http://www.fao.org/docrep/006/x0413e/X0413E02.htm>]


S l i d e  6	<h2>HISTORY</h2>	
S l i d e  7	<h3>History</h3> <ul style="list-style-type: none"> <li>• Originated in Asia             <ul style="list-style-type: none"> <li>- May have been introduced to Europe through importation of stallions</li> <li>- Outbreaks reported in:                 <ul style="list-style-type: none"> <li>• Germany</li> <li>• France</li> <li>• Austria</li> <li>• Switzerland</li> <li>• Algeria</li> </ul> </li> </ul> </li> </ul>	<p>Dourine is believed to have originated in Asia, and may have been introduced into Europe through the importation of Arabian stallions. Outbreaks were reported in Germany, France, Austria, and Switzerland, as well as in Algeria. Reference: Derbyshire JB, Nielsen NO. Edward Watson and the eradication of dourine in Canada, Veterinary History. Can Vet J. 1997 Sept;38.</p>
S l i d e  8	<h3>History</h3> <ul style="list-style-type: none"> <li>• Introduced to North America             <ul style="list-style-type: none"> <li>- Stallion imported from France in 1882</li> <li>- Outbreaks occurred in:                 <ul style="list-style-type: none"> <li>• Illinois (1886)</li> <li>• Nebraska (1892 and 1898)</li> <li>• South Dakota (1901)</li> <li>• Iowa (1903)</li> <li>• Canada (1904)</li> </ul> </li> </ul> </li> </ul>	<p>The disease was introduced into North America by a Percheron stallion imported into Illinois from France in 1882. Outbreaks occurred in the United States in Illinois [1886], Nebraska [1892 and 1898], South Dakota [1901], and Iowa [1903], before the disease appeared in Canada in 1904. Reference: Derbyshire JB, Nielsen NO. Edward Watson and the eradication of dourine in Canada, Veterinary History. Can Vet J. 1997 Sept;38.</p>
S l i d e  9	<h2>EPIDEMIOLOGY</h2>	
S l i d e  10	<h3>Epidemiology</h3> <ul style="list-style-type: none"> <li>• Dourine once widespread             <ul style="list-style-type: none"> <li>- Now eradicated from many countries</li> </ul> </li> <li>• Endemic             <ul style="list-style-type: none"> <li>- Parts of Africa and Asia, including Russia</li> </ul> </li> <li>• Outbreaks             <ul style="list-style-type: none"> <li>- Middle East</li> <li>- Europe</li> </ul> </li> </ul> 	<p>Dourine was once widespread, but it has been eradicated from many countries. Currently, the disease is endemic in parts of Africa and parts of Asia including Russia. Outbreaks or cases are occasionally reported from other areas including the Middle East and Europe.</p> <p>[Photo: This map shows the reported cases of dourine in animals worldwide (January-June 2013). Red indicates a current disease event, purple indicates disease limited to one or more zones, dark green indicates disease not reported in this period, and light green indicates disease never reported]</p>

<p>S l i d e  1 1</p>	<p style="text-align: center;"><b>TRANSMISSION</b></p>	
<p>S l i d e  1 2</p>	<p style="text-align: center;"><b>Transmission</b></p> <ul style="list-style-type: none"> <li>• Transmitted during breeding             <ul style="list-style-type: none"> <li>- Stallion-to-mare most common                 <ul style="list-style-type: none"> <li>• Occasional mare-to-stallion</li> </ul> </li> <li>- Found in:                     <ul style="list-style-type: none"> <li>• Vaginal secretions</li> <li>• Seminal fluid</li> <li>• Exudate from the penis</li> </ul> </li> <li>- Non-infectious periods possible                     <ul style="list-style-type: none"> <li>• Parasites may temporarily disappear</li> <li>• More common in late disease</li> </ul> </li> </ul> </li> </ul>	<p>Unlike other trypanosomal infections, dourine is transmitted almost exclusively during breeding. Transmission from stallions to mares is more common, but mares can also transmit the disease to stallions. <i>T. equiperdum</i> can be found in the vaginal secretions of infected mares and the seminal fluid, mucous exudate of the penis, and sheath of stallions. Periodically, the parasites disappear from the genital tract and the animal becomes noninfectious for weeks to months. Noninfectious periods are more common late in the disease.</p>
<p>S l i d e  1 3</p>	<p style="text-align: center;"><b>Transmission</b></p> <ul style="list-style-type: none"> <li>• Asymptomatic carriers             <ul style="list-style-type: none"> <li>- Male donkeys</li> </ul> </li> <li>• Mare-to-foal transmission             <ul style="list-style-type: none"> <li>- Before birth</li> <li>- Through milk or mucous membranes</li> </ul> </li> <li>• No evidence of arthropod vectors</li> <li>• Sexually immature animals             <ul style="list-style-type: none"> <li>- Can transmit organism at maturation</li> </ul> </li> </ul> 	<p>Male donkeys can be asymptomatic carriers. Rarely, infected mares pass the infection to their foals, possibly before birth or through the milk. Infections are also thought to occur through mucous membranes such as the conjunctiva. Other means of transmission may also be possible; however, there is currently no evidence that arthropod vectors play any role in transmission. Sexually immature animals that become infected can transmit the organism when they mature. [Photo: Donkey. Source: Wikimedia Commons]</p>
<p>S l i d e  1 4</p>	<p style="text-align: center;"><b>DISEASE IN HUMANS</b></p> <p>There is no evidence that <i>T. equiperdum</i> can infect humans.</p>	
<p>S l i d e  1 5</p>	<p style="text-align: center;"><b>DISEASE IN ANIMALS</b></p>	

S  
I  
d  
e  
1  
6

**Species Affected**

- Horses, donkeys, and mules
  - Only natural reservoirs
  - Zebras positive by serology
  - Ruminants not susceptible to equid isolates
- Experimental infection
  - Dogs, rabbits, rats, mice



Dourine mainly affects horses, donkeys and mules. These species appear to be the only natural reservoirs for *T. equiperdum*. Zebras have tested positive by serology, but there is no conclusive evidence of infection. Ruminants do not seem to be susceptible to the isolates from equids. Dogs, rabbits, rats and mice can be infected experimentally.

[Photo: Horse. Source: U.S. Department of Agriculture]

S  
I  
d  
e  
1  
7

**Disease in Animals**


- Incubation: weeks to years
- Symptoms variable
  - Strain virulence
  - Nutritional status
  - Stress factors
- Signs may wax and wane
  - Can occur several times before animal dies or recovers

The incubation period is a few weeks to several years. The symptoms vary with the virulence of the strain, the nutritional status of the horse, and stress factors. The clinical signs often develop over weeks or months. They frequently wax and wane; relapses may be precipitated by stress. This can occur several times before the animal either dies or experiences an apparent recovery.

S  
I  
d  
e  
1  
8

**Disease in Animals**

- Clinical signs
  - Genital edema
  - Mucopurulent discharge
  - Vulvitis, vaginitis, polyuria
  - Raised and thickened patches on vaginal mucosa
  - Swollen membranes
    - Can protrude through vulva




Genital edema and a mucopurulent discharge are often the first signs. Mares develop a mucopurulent vaginal discharge, and the vulva becomes edematous; this swelling may extend along the perineum to the ventral abdomen and mammary gland. Vulvitis, vaginitis with polyuria, and signs of discomfort may be seen. Raised and thickened semitransparent patches may be seen on the vaginal mucosa of some mares, and swollen membranes can protrude through the vulva.

[Photo: Vulvar thickening and edema, often gelatinous, due to *Trypanosoma equiperdum*. Source: Armed Forces Institute of Pathology/CFSPH]

S  
I  
d  
e  
1  
9

**Disease in Animals**

- Depigmentation
  - Genital region, perineum, udder
- Abortion
- Edema of prepuce and glans penis
  - May spread to the scrotum, perineum, ventral abdomen, and thorax
- Leukodermic patches



The genital region, perineum and udder may become depigmented. Abortion can occur with more virulent strains. Stallions develop edema of the prepuce and glans penis, and can have a mucopurulent discharge from the urethra. In stallions, the swelling may spread to the scrotum, perineum, ventral abdomen and thorax. Vesicles or ulcers can also occur on the genitalia; when they heal, these ulcers can leave permanent white scars called leukodermic patches.

[Photo: Edema of the prepuce. Source: USAHA Foreign Animal Diseases (Grey Book) at [http://www.aphis.usda.gov/emergency\\_response/downloads/nahems/fad.pdf](http://www.aphis.usda.gov/emergency_response/downloads/nahems/fad.pdf)]

S  
I  
d  
e  
2  
0

<p><b>Disease in Animals</b></p> <ul style="list-style-type: none"> <li>• "Silver dollar plaques"                             <ul style="list-style-type: none"> <li>- Skin, particularly over the ribs</li> <li>- Pathognomonic</li> </ul> </li> <li>• Neurological signs                             <ul style="list-style-type: none"> <li>- Develop after genital edema, or weeks to months later</li> <li>- Eventual paralysis</li> </ul> </li> <li>• Other signs                             <ul style="list-style-type: none"> <li>- Conjunctivitis, anemia, emaciation</li> </ul> </li> </ul>
-------------------------------------------------------------------------------------------------------------------------------------------------------------------------------------------------------------------------------------------------------------------------------------------------------------------------------------------------------------------------------------------------------------------------------------------------------------------------------------------------------------------------------------------------------------------------------------------------------

Edematous patches called "silver dollar plaques" (up to 10 cm diameter and 1 cm thick) may appear on the skin, particularly over the ribs. These cutaneous plaques usually last for 3 to 7 days and are pathognomonic for the disease. They do not occur with all strains. Neurological signs can develop soon after the genital edema, or weeks to months later. Restlessness and weight shifting from one leg to another is often followed by progressive weakness, incoordination and, eventually, paralysis. Facial paralysis, which is generally unilateral, may be seen in some animals. Conjunctivitis and keratitis are common, and in some infected herds, ocular disease may be the first sign of dourine. Anemia and intermittent fever may also be found. In addition, dourine results in a progressive loss of condition, predisposing animals to other diseases. Affected animals may become emaciated, although the appetite remains good.

S  
I  
d  
e  
2  
1

<p><b>Morbidity and Mortality</b></p> <ul style="list-style-type: none"> <li>• Morbidity variable                             <ul style="list-style-type: none"> <li>- Chronic, mild disease</li> <li>- Acute, severe disease</li> </ul> </li> <li>• Mortality                             <ul style="list-style-type: none"> <li>- Untreated cases: 50 to 70%</li> <li>- Endemic areas                                     <ul style="list-style-type: none"> <li>• Drug treatment may be possible</li> <li>• Treatment may result in inapparent carriers</li> </ul> </li> </ul> </li> </ul>
-----------------------------------------------------------------------------------------------------------------------------------------------------------------------------------------------------------------------------------------------------------------------------------------------------------------------------------------------------------------------------------------------------------------------------------------------------------------------------------------------------------------------------------------------------------------------------------------------

Severity of disease is variable. The prevalent strains in southern Africa tend to cause a chronic, mild disease that may last for several years. In South America and northern Africa, cases have been more acute, often lasting only one to two months. More severe disease is usually seen in improved breeds of horses, while donkeys, mules and native ponies tend to be more resistant. The mortality rate in untreated cases is estimated to be 50 to 70%. In endemic areas, drug treatment may be possible; however, treatment may result in inapparent disease carriers.

S  
I  
d  
e  
2  
2

<p><b>Diagnosis</b></p> <ul style="list-style-type: none"> <li>• Clinical diagnosis                             <ul style="list-style-type: none"> <li>- Genital edema, neurological signs, "silver dollar plaques"</li> </ul> </li> <li>• Differentials                             <ul style="list-style-type: none"> <li>- Coital exanthema</li> <li>- Surra, anthrax</li> <li>- Equine viral arteritis</li> <li>- Equine infectious anemia</li> <li>- Contagious equine metritis</li> </ul> </li> </ul>
-------------------------------------------------------------------------------------------------------------------------------------------------------------------------------------------------------------------------------------------------------------------------------------------------------------------------------------------------------------------------------------------------------------------------------------------------------------------------------------------------------------

Symptoms suggestive of dourine include genital edema and neurological signs. "Silver dollar plaques," if present, are pathognomonic. Diagnosis can be difficult in some cases, particularly in the early stages or during latent infections. The differential diagnosis includes coital exanthema, surra, anthrax, equine infectious anemia, equine viral arteritis and causes of purulent endometritis such as contagious equine metritis.

S  
I  
d  
e  
2  
3


<p><b>Diagnosis</b></p> <ul style="list-style-type: none"> <li>• Serology + clinical signs                             <ul style="list-style-type: none"> <li>- Complement fixation                                     <ul style="list-style-type: none"> <li>• Prescribed test for international trade</li> <li>• Used successfully in eradication programs</li> <li>• False positives in uninfected animals</li> </ul> </li> <li>- ELISA, radioimmunoassay</li> <li>- Counter immunoelectrophoresis</li> <li>- Agar gel immunodiffusion</li> </ul> </li> <li>• Cross-reactions may occur</li> </ul>
--------------------------------------------------------------------------------------------------------------------------------------------------------------------------------------------------------------------------------------------------------------------------------------------------------------------------------------------------------------------------------------------------------------------------------------------------------------------------------------------------------------------------------------------------------------------------------------------------------

Dourine is usually diagnosed by serology combined with clinical signs. The complement fixation test is the prescribed test for international trade, and has been used successfully in eradication programs. However, uninfected animals, particularly donkeys and mules, often have inconsistent or nonspecific reactions (false positives) due to anticomplementary effects in equid serum. Indirect fluorescent antibody tests may help to resolve these cases. Other serologic tests include enzyme linked immunosorbent assays (ELISAs), radioimmunoassay, counter immunoelectrophoresis, agar gel immunodiffusion (AGID) and card agglutination. Cross-reactions can occur with Old World trypanosomes, especially *T. brucei* and *T. evansi*, and no serological test is specific for dourine.

S  
I  
d  
e  
2  
4

**Laboratory Tests**

- Parasite identification
  - Definitive diagnosis
  - Difficult to find
    - Lymph, edematous fluids of external genitalia, vaginal mucus, fluid content of plaques
  - Detection more likely after edema and plaques first appear
  - Rarely found in thick blood films



Definitive diagnosis is by identification of the parasite; however, the organisms are extremely difficult to find. A small number of trypanosomes may be found in the lymph, edematous fluids of the external genitalia, vaginal mucus, and fluid content of plaques. Detection is more likely shortly after the edema or plaques first appear. On rare occasions, the trypanosomes can be found in thick blood films; however, the parasites are present very transiently in the blood, and are usually undetectable. [Photo: *Trypanosoma* organism (purple) in a blood smear. Source: USAHA Foreign Animal Diseases (Grey Book) at [http://www.aphis.usda.gov/emergency\\_response/downloads/nahems/fad.pdf](http://www.aphis.usda.gov/emergency_response/downloads/nahems/fad.pdf)]

S  
I  
d  
e  
2  
5

**Sampling**


- Before collecting or sending any samples, the proper authorities should be contacted
- Samples should only be sent under secure conditions and to authorized laboratories to prevent the spread of the disease

Before collecting or sending any samples from animals with a suspected foreign animal disease, the proper authorities should be contacted. Samples should only be sent under secure conditions and to authorized laboratories to prevent the spread of the disease.

S  
I  
d  
e  
2  
6

**Samples to Collect**

- Serum
- Whole blood
  - Blood smears
- "Silver dollar plaques"
  - Aspirated fluid; re-examine periodically
- Vaginal and preputial washings or scrapings
  - 4 to 5 days after infection



Serum, whole blood in EDTA and blood smears should be submitted. If silver dollar plaques are present, the skin over a plaque can be washed, shaved and dried, and the fluid aspirated with a syringe to look for trypanosomes. Because trypanosomes only occur for a few days in plaques, the lesions should be reexamined periodically. Organisms may sometimes be found in vaginal or preputial washings or scrapings taken 4 to 5 days after infection. [Photo: Serum samples. Source: Danelle Bickett-Weddle/CFSPH]

S  
I  
d  
e  
2  
7

**PREVENTION AND CONTROL**

S  
I  
d  
e  
2  
8

**Recommended Actions**

- IMMEDIATELY notify authorities
- Federal
  - Area Veterinarian in Charge (AVIC) [http://www.aphis.usda.gov/animal\\_health/area\\_offices/](http://www.aphis.usda.gov/animal_health/area_offices/)
- State
  - State veterinarian <http://www.usaha.org/stateanimalhealthofficials.aspx>
- Quarantine

If you suspect dourine infection, state or federal authorities should be notified immediately. Animals suspected with dourine should be isolated, and the farm should be quarantined until definitive diagnosis is determined.

S  
I  
d  
e  
2  
9

**Prevention and Control**


- New animals
  - Quarantine
  - Serological testing
  - Cease breeding if detected
- Herd eradication
  - Infected animals euthanized
  - Stallions castrated
    - Geldings can spread disease if they display copulatory behavior

To prevent dourine from being introduced into a herd or region, new animals should be quarantined and tested by serology. When dourine is found in an area, quarantines and the cessation of breeding can prevent transmission while infected animals are identified. Dourine can be eradicated from a herd, using serology to identify infected equids. Infected animals are euthanized. In some cases, stallions have been castrated to prevent disease transmission; however, geldings can still transmit the disease if they display copulatory behavior.

S  
I  
d  
e  
3  
0

**Prevention and Control**

- *T. equiperdum* cannot survive outside a living organism
- Disinfection
  - 1% sodium hypochlorite
  - 2% glutaraldehyde
  - 2% formaldehyde
  - Heat at 50 to 60°C



*T. equiperdum* cannot survive outside a living organism, and dies quickly with its host. If necessary, this organism can be destroyed by various disinfectants including 1% sodium hypochlorite, 2% glutaraldehyde and formaldehyde, as well as heat of 50-60° C.

[Photo: Disinfectants. Source: Danelle Bickett-Weddle/CFSPH]

S  
I  
d  
e  
3  
1

**Treatment**

- Successful treatment reported in some endemic regions
  - Trypanocidal drugs
- Usually discouraged
  - Likelihood of inapparent persistence
- Good hygiene should at assisted breedings
- No vaccine available

Successful treatment with trypanocidal drugs has been reported in some endemic areas. However, therapeutic regimes have not been thoroughly investigated, and treatment is usually discouraged due to fears that the organism will persist inapparently. Good hygiene should be used at assisted matings. No vaccine is available.

S  
I  
d  
e  
3  
2

**Additional Resources**

- Center for Food Security and Public Health
  - [www.cfsph.iastate.edu](http://www.cfsph.iastate.edu)
- USAHA Foreign Animal Diseases ("The Gray Book")
  - [www.aphis.usda.gov/emergency\\_response/downloads/nahems/fad.pdf](http://www.aphis.usda.gov/emergency_response/downloads/nahems/fad.pdf)

Last updated December 2011.

S  
I  
d  
e  
3  
3

**Acknowledgments**

Development of this presentation was made possible through grants provided to the Center for Food Security and Public Health at Iowa State University, College of Veterinary Medicine from the Centers for Disease Control and Prevention, the U.S. Department of Agriculture, the Iowa Homeland Security and Emergency Management Division, and the Multi-State Partnership for Security in Agriculture.

**Authors:** Ariel Pleva, MPH; Kerry Leedom Larson, DVM, MPH, PhD, DACVPM  
 Anna Rovid Spickler, DVM, PhD  
**Reviewers:** Glenda Dvorak, DVM, MPH, DACVPM